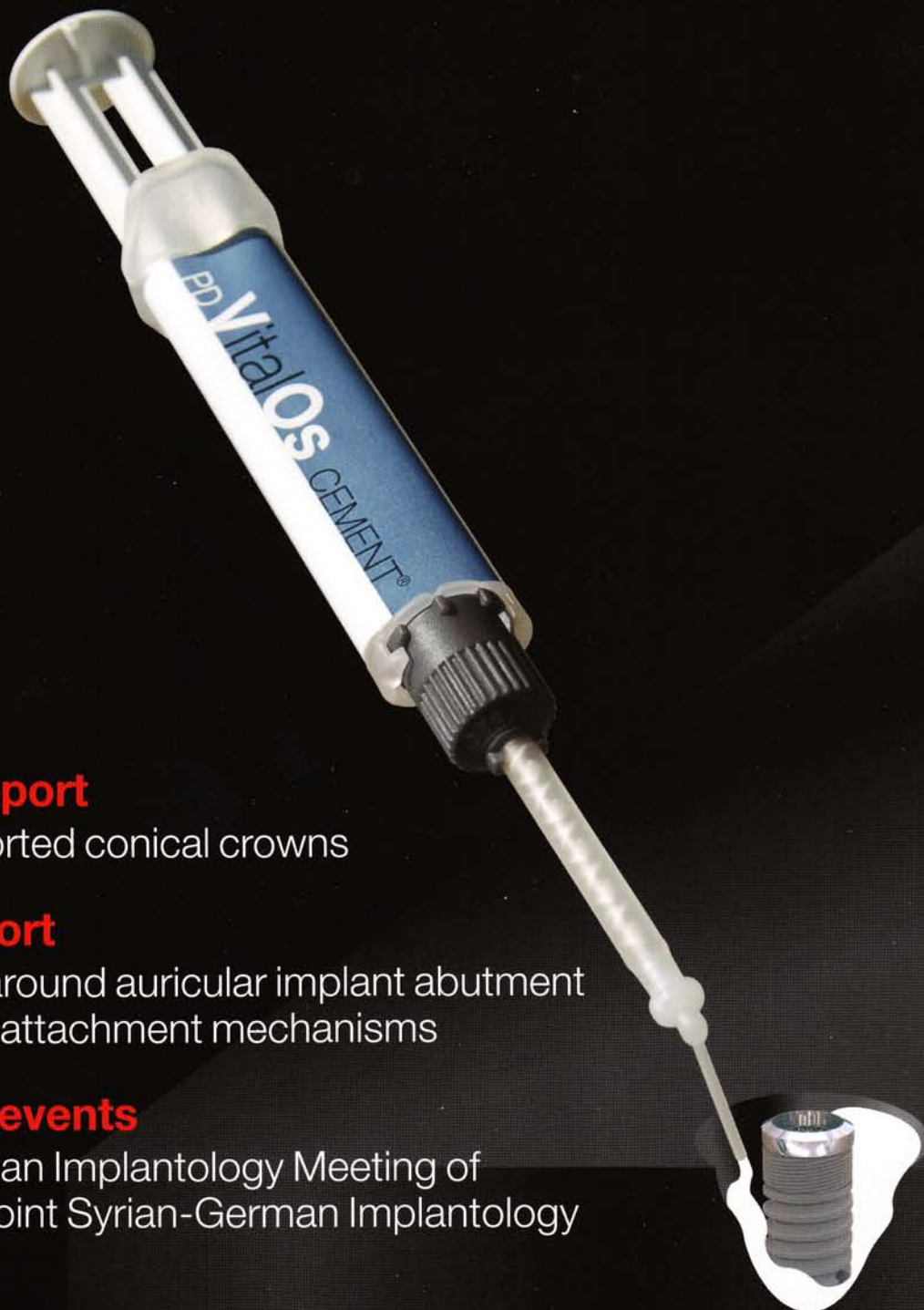

implants

international magazine of oral implantology

1 2009



_implants report

Implant-supported conical crowns

_clinical report

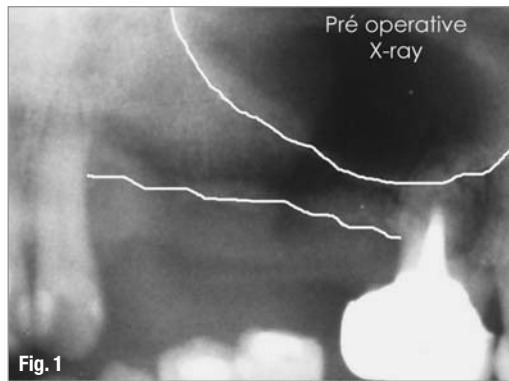
Skin reaction around auricular implant abutment using different attachment mechanisms

_worldwide events

5th Arab-German Implantology Meeting of DGZI and 1st Joint Syrian-German Implantology Meeting

Use of Bone Regeneration Cement for Bone Grafting in Atrophic Areas—Clinical, Radiographic and Histological Analysis

authors_ Sérgio Alexandre Gehrke*, Bruno König Júnior**, Nara Maria Beck Martins***, *Lachem, Universidade Federal de Santa Maria, Brazil, ** ICB, Universidade de São Paulo, Brazil, *** Dpt. of Pathology, Universidade Federal de Santa Maria, Brazil



_Abstract

The reconstruction of edentulous jaws aims first at augmenting the ridge width by gaining volume, and then at promoting growth of healthy and functional bone, able to support the prosthetic implant restoration over many years. The bone atrophy following tooth loss is due to a lack of mechanical stimulation and is emphasized by the pressure applied by the prosthesis and—in the posterior region—by the progressive pneumatization of the maxillary sinuses. The challenge of bone augmentation materials is to promote sufficient bone capital allowing adequate placement of implants. Nowadays, thanks to the recent breakthrough in understanding of cell metabolism, there is a great

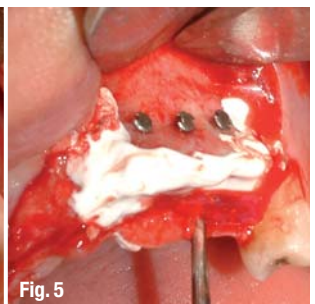
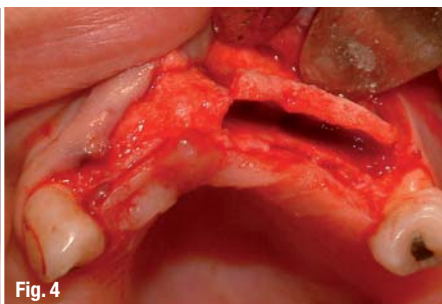
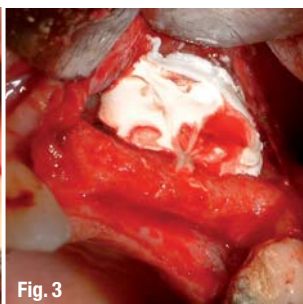
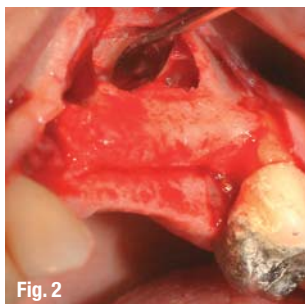
trend to develop synthetic materials for this purpose, in order to decrease the surgical trauma and the number of interventions. This is reflected by the number of products available on the market.

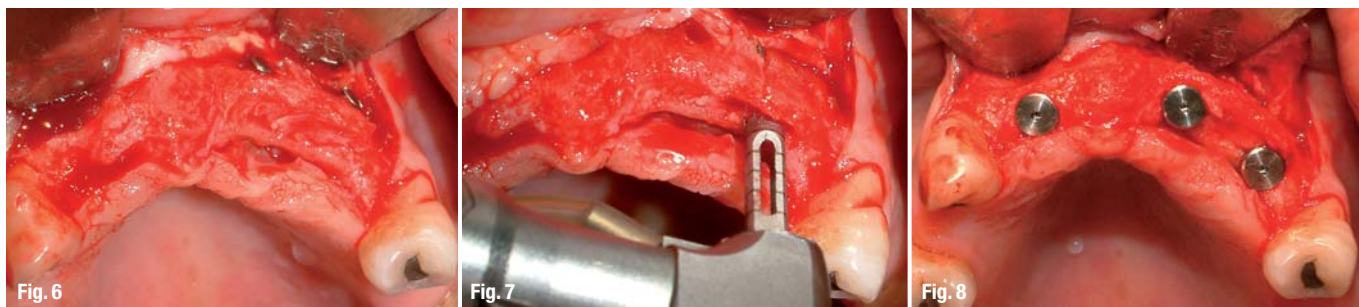
PD VitalOs Cement is a relatively new synthetic bone substitute that has been extensively studied in animal models. Although its use in clinical practice has shown positive results already, the histological data still needs to be developed and studied in details. The objective of this study is to evaluate the performance of PD VitalOs Cement for the osseous regeneration of atrophic areas to allow subsequent placement of dental implants. Performance is assessed through clinical and radiological follow-up as well as histological examination to evaluate the osteogenic potential of the material in six patients. The selected indications for this study are the sinus floor elevation and the horizontal ridge augmentation, two procedures performed in two steps, allowing collection of cores when installing the implants.

_Introduction and literature review

Successful augmentation of ridge margins is achieved when two requirements are fulfilled: on the one hand healthy and functional bone able to support implant-supported prosthetic restorations in function over years and on the other hand,

Fig. 1_ Pre-operative radiograph.
Figs. 2, 3_ Preparation of the site and installation of the cement in the sinus.
Figs. 4 – 6_ Illustration of the horizontal ridge augmentation technique.





Figs. 7–9 Collection of cores for the histological examination.

the gain of a sufficient bone volume to preserve esthetics. The main reason for using bone substitute materials is to allow tissue regeneration through viable, healthy and mature bone in areas where implantation is planned. Various degrees of atrophy are encountered in the maxilla and mandible of patients. They vary with the etiology of teeth loss, such as periodontal disease, systemic health problems, anatomy, trauma, agenesis, among other factors. This atrophy for lack of stimulation of the bone after tooth loss is even enhanced by the pressure applied by the edges of the prosthesis and, more posteriorly, by the progressive pneumatization of the maxillary sinuses. Initially, the alveolar process loses width without height loss. This phenomenon starts buccally and progresses towards the lingual or palatal direction. It takes place relatively quickly, especially in the anterior region of the maxilla, so that the implants of usual diameter cannot be placed due to the insufficient width for the preparation of the bone bed. The severe bone loss results in a lack of support for the soft gum tissues as well as for the upper lip and facial soft tissue, leading to unsatisfactory esthetic results.

It is important to keep in mind that following tooth loss, the process of bone loss can be lessened or even prevented by the installation of implants as soon as possible, before progressive atrophy starts. Masticatory loads transmitted through the implants to the alveolar maxillary sockets stimulate the bone and therefore contribute to diminishing or even avoiding the progressive bone atrophy. Nevertheless, when these conditions are not achieved it becomes necessary to recover the lost bone anatomy through various techniques and materials. The actual trend is to perform surgeries as little invasive as possible and with a high predictability.

The need for correction of bone defects has led to the development of synthetic materials reproducing biological properties required for bone grafting. Autologous graft is generally considered the most suitable material to correct such defects. However, use of autologous bone is not always an option when the defect size is too large or when patient discomfort would be too important or when his recovery would take too long.¹⁻⁶

The ideal synthetic bone substitute should be biocompatible, gradually resorbed and eventually replaced by the host tissue (osteoconductive or osteoinductive properties)⁷⁻¹¹ Beside these biological properties and availability, the stabilization of the implantation site is an interesting feature in various operative situations.¹² Given that few techniques and materials present all these requisites, the dental surgeon needs to have choice criteria to choose the adequate technique and material for different situations.

The use of biomaterials in clinical dentistry is gaining increasing importance in light of the various possibilities of application and ease of use they offer. The use of alloplastic bone substitutes is indicated to restore the function and morphology of areas that have suffered surgical interventions, to increase the volume of atrophied alveolar ridges, or to treat lesions caused by periapical diseases, periodontal bone defects, bone loss associated or not to implants, etc.¹³⁻¹⁸

Calcium-based substitute materials have been widely studied over the last twenty years, mainly due to the relative ease of production and the possibility to produce large quantities. Among these, cements were also developed to facilitate the installation of such materials in bone defects. The use of a cement as bone substitute offers in-

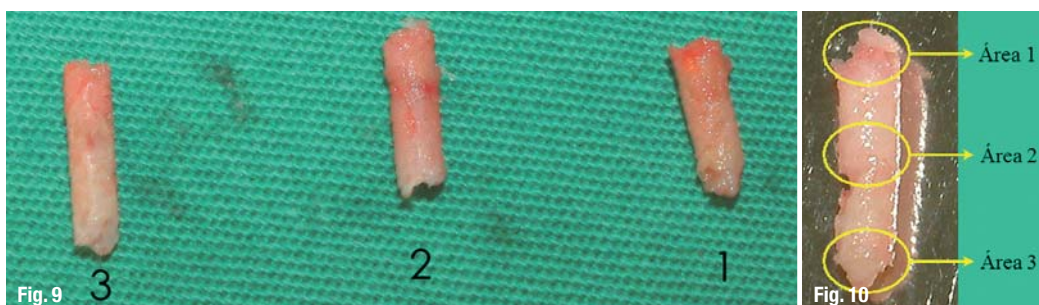
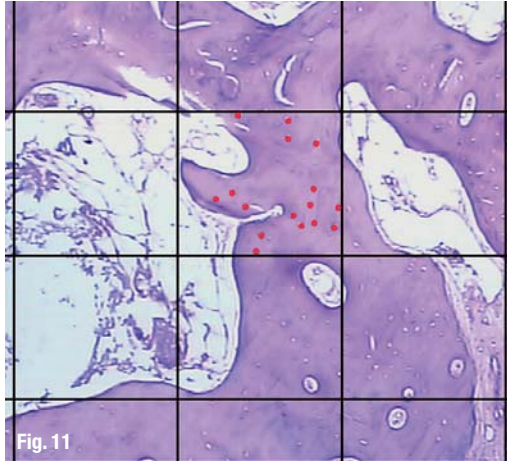


Fig. 10 Division of the cores into three analysis areas.

Fig. 11 Illustration of the histological analysis for counting the number of osteocytes per mm².



interesting features, like the setting reaction leading to stabilization of the treated site or the ease of placement. However, there are some clinical requisites that must be fulfilled, like easy handling of the product, adequate setting time, sufficient mechanical strength between placement and complete resorption, neutral pH (6.5–8.5) during and after setting to prevent any cytotoxic effect, and good adherence to bone tissue.

Bone cements offer a very interesting alternative to granular bone substitutes. The first difference to granules is that they harden in situ and are therefore mechanically stable in their environment. This means that they can be used without membrane to hold them in place, like it is done with granular products to avoid their secondary migration. The other reason why a membrane is not necessary is related to the inner structure of a cement. The porosity of the material is too narrow to allow cells, blood vessels and soft tissues to penetrate the cement. Bone regeneration takes place at the bone-cement interface, which moves over time towards the heart of the material.^{19, 20} The fact that the surgery is then performed without handling a membrane lowers the overall cost and the per-operative time.

The present study aims at evaluating clinically, radiographically and histologically the performance of an injectable calcium phosphate cement (PD VitalOs Cement) used to fill bone defects in patients requiring subsequent implant installation.

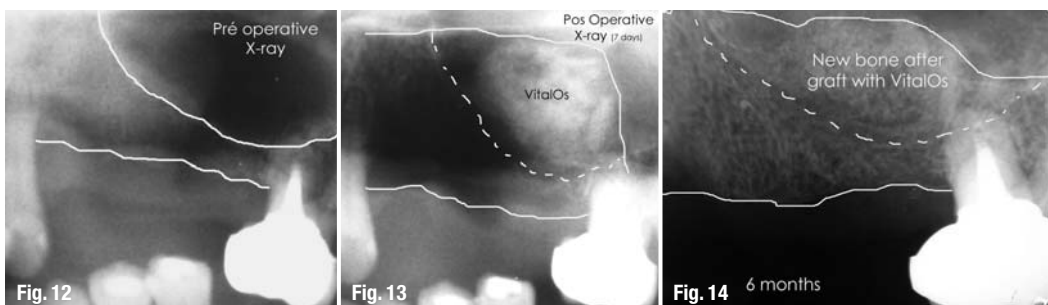
Materials and Methods

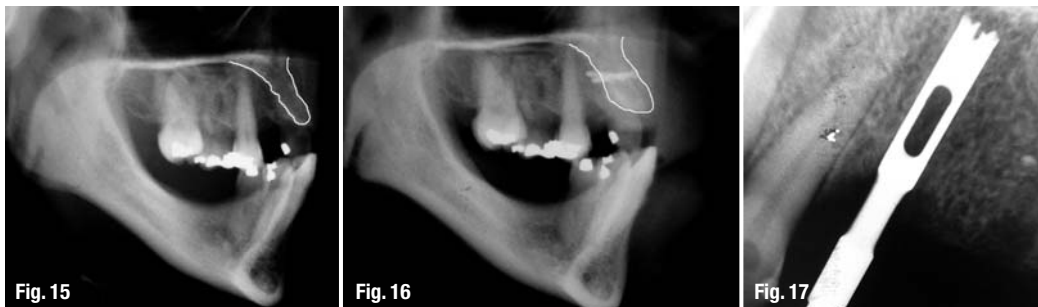Six patients of the Bioface Institute were selected for the study, three requiring sinus floor augmentation (without concomitant placement of implants—two-stage procedure) (group 1) and three requiring maxillary buccal augmentation through ridge distraction (group 2). The selected patients had all a good general health, without major disease history or contra-indication for the proposed reconstructive surgery. They all agreed in written with the proposed treatment guidelines, and received pre- and post-operative antibiotics and anti-inflammatory treatment.

In patients of the group 1 (G1) maxillary sinuses were filled with the cement (Figs. 1–3). The treated sites presented conditions where simultaneous implantation was not possible. The intervention was performed through opening of a lateral window. When lifting the sinus membrane, attention was paid to uncover the lateral bone wall of the nasal cavity. The filling of the sinus was performed by injecting the cement while holding the membrane lifted with an instrument. It is very important to ensure a good anchoring of the cement against the bone wall of the nasal cavity since the latter provides the osteogenic cells for the replacement of the cement by new bone. To achieve this it is necessary to control the bleeding in the sinus. Stability of the cement in the site is effective once it is anchored to the inner side of the sinus (nasal cavity) and its outer part (the inner side of the ridge around the lateral window) (Figs. 1–3). After 6 months, every implantation site was drilled with a trephine bur (external diameter 3 mm) in order to get cores for histological examination.

The patients in group 2 (G2) required bone volume augmentation in the anterior maxilla. The technique chosen was a horizontal ridge augmentation allowing in the same time the correction of the lip position. The empty spaces created by the distraction were in average 4 mm wide and were filled with the cement, starting from the bottom, up to the level of the ridge. The implants were placed four months later. The implantation sites were drilled with a trephine bur to collect cores for histological examination.

Figs. 12–14 Radiographic sequence showing the evolution of the augmentation material in the sinus (pre-op, post-op, 6 months follow-up).





Figs. 15, 16_ Lateral radiographs, pre-operative and after 4 months. **Figs. 17, 18_** Radiograph showing collection of a core in native bone and corresponding histological section of this area with 10x magnification (HE).

In both groups, samples of native bone (NB) were obtained by drilling in neighboring implantation sites where no augmentation was previously performed (Figs. 4–9).

G1 patients were controlled by conventional panoramic radiographs at one week and six months post-operatively. G2 patients were additionally followed up with profile radiographs one week and four months after surgery.

The cores were dehydrated, embedded in paraffin, then cut into sections. The latter were stained with the Hematoxylin and Eosin (HE) and the Masson's trichrome (TM) methods.²¹

All observations were made with a light microscope Nikon E200 coupled to a camera. The comparison between native bone and augmented areas was made by analyzing quantitatively the number of osteocytes per square mm. The measurements were performed at three levels of the cores (areas 1 to 3, external to apical parts), as shown in Figs. 10 and 11. The analysis was made on images with a 10x magnification. The results are presented in Table 1, in the form of mean values from the data of three patients, for each core area considered. The data was analyzed with the variance analysis test (Anova two way, with software GraphPad Prism® 4.0, $p < 0.05$).

Area	Native bone	G 1	G 2
1	7.33	19.33	14.33
2	6.33	14.66	19
3	8.66	16.66	17.66

Table 1_ Mean number of osteocytes per mm² in each area.

A descriptive and semi-quantitative analysis was performed, considering the following factors involved in bone healing: cortical repair, collagen fibers, inflammatory infiltrate and new bone formation (Tables 2 and 3). The notation system used was the following: Collagen fibers, inflammatory infiltrate and new bone formation: 0 = absent, 1 = light, 2 = moderate, 3 = large presence. Cortical repair: 0 = absent, 1 = irregular union of margins, 2 = covering around 50% of the core width, 3 = width larger than 50% of the core width. The data presented in Tables 2 and 3 are mean values of the three core areas.

The sections were analyzed by a single examiner with experience in analysis of bone tissue histological sections.

Patient	Cortical repair	Collagen fibers	Inflammatory infiltrate	New bone formation
I	2	2	1	3
II	3	2	1	3
III	2	1	0	3

Table 2_ Semi-quantitative analysis, G1.

Patient	Cortical repair	Collagen fibers	Inflammatory infiltrate	New bone formation
I	3	1	0	3
II	3	1	0	3
III	3	2	1	3

Table 3_ Semi-quantitative analysis, G2.

_Results

Clinical

No complication of any type was reported among the six patients involved in the study in the course of the whole treatment: no per-operative complication (two surgeries per patient) and no post-operative complication (post-operative study

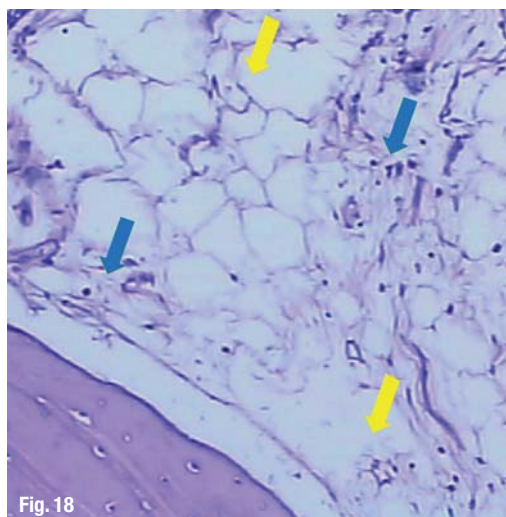
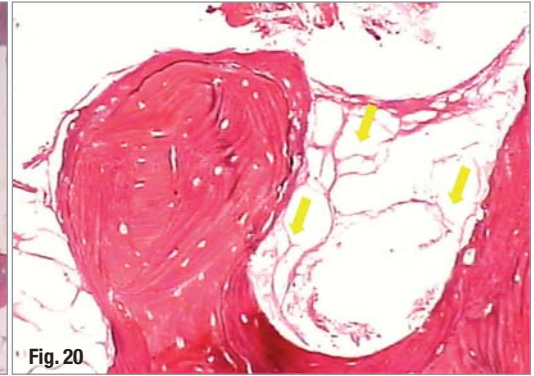
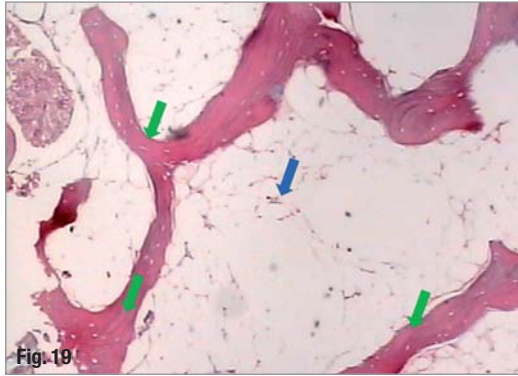


Fig. 18

Figs. 19, 20_ Histology of native bone with 10x and 40x magnification (TM).



time: six months for G1 patients, four months for G2 patients).

Upon suture removal, the healing process was uneventful, similar to cases usually treated with autologous bone. The installation of well osseointegrated implants was possible in the second surgical procedure and the implant-supported prostheses have all been placed successfully.

The bone tissue in the implantation sites had always a firm consistency, similar to normal type II bone tissue, with a good resistance to the drilling performed with rotary instruments. This allowed placement of implants with good primary stability.

Radiographs

Thanks to its radiopacity, the cement was easily located on the post-op radiographs taken at one week, especially in the G1 cases (Fig. 13). This allowed to distinguish clearly on the subsequent radiographs the resorption of the cement and the formation of new bone. After six months the presence of new bone can be clearly evidenced in the sinuses (Figs. 12–14). In the G2 the volume gained 4 months after the augmentation procedure can also be clearly evidenced on the radiographs (Figs. 15 and 16). This allowed adequate installation of implants, facilitating the final esthetic result.

Histologies

The number of osteocytes per square mm was found to be statistically different between NB (native bone) and G1 and G2 (Anova analysis, $p < 0.05$), the

augmented groups showing more osteocytes than in native bone (Table 1). No statistical difference was evidenced between the two augmented groups (G1 and G2).

The semi-quantitative analysis of the cores showed similar results in group 1 and 2.

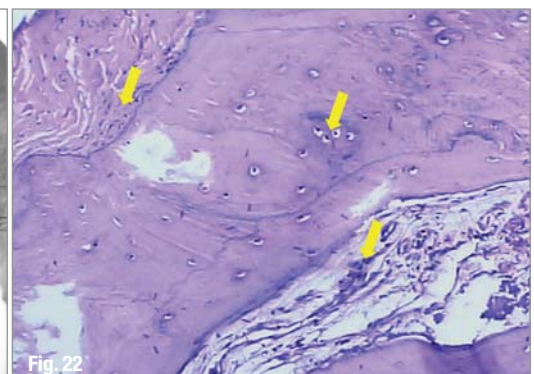
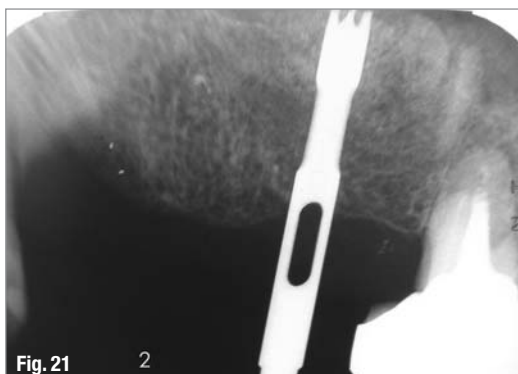
Native bone

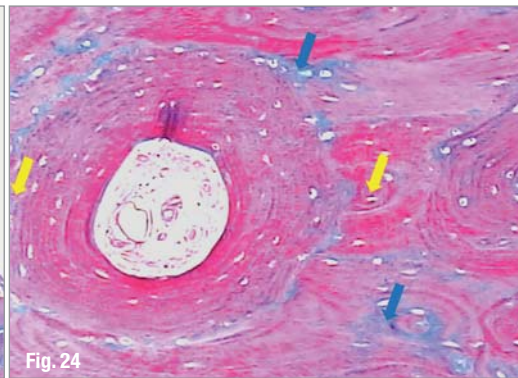
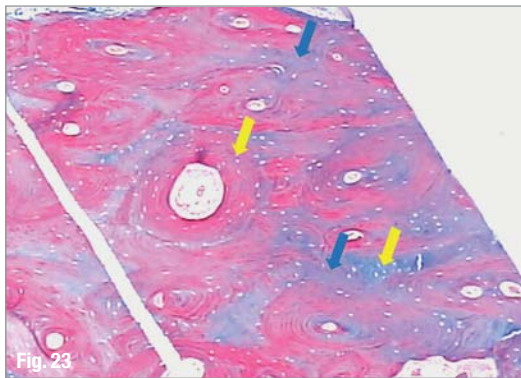
The histological analysis of the cores taken in native bone shows a trabecular structure typical of cancellous bone, like narrow trabeculae (green arrows) with lines of incremental growth and presence of many viable cells (osteocytes—blue arrows) in all patients under evaluation. The medullary spaces had a normal aspect, without inflammatory infiltrate, with blood vessels free of congestion and cells resembling adipocytes (bone marrow fat—yellow arrow), as shown in Figs. 17–20.

Areas augmented with bone regeneration cement

The histologies gathered from sinuses augmented with the cement (G1) show new bone formation, although the quantity and density of the trabeculae is inferior to those found in those of G2. The spaces where calcification was not complete show a large quantity of blood vessels and collagen fibers with intensive cellular activity (yellow arrows). Some areas presented a conjunctive tissue, rich in collagen fibers and with only few cells. In none of the sections studied was there any remnant of unresorbed cement to be seen (Figs. 21–25). In the areas augmented with the

Figs. 21, 22_ Radiograph showing the collection of a core (G1), and resulting histology (10x – HE).





Figs. 23–25_ Histological section from G1, magnified 4, 10 and 40x (TM).

cement in the G2 group (ridge distraction) intensive new bone formation can be seen, with a trabecular density higher than in the native bone (green arrows). The trabeculae are made of viable cells (osteocytes, blue arrows), as well as several incremental growth lines, with newly formed bone observed in the form of lamellar bone in these areas. The non-calcified spaces augmented with the cement show the presence of collagen fibers with intensive cellular activity (yellow arrow). The presence of dilated blood vessels was noted, indicating intensive vascularization in the new bone formation areas (Figs. 26 – 30). Like in the histo-

logical sections of G1, none of the G2 sections showed any cement remnant.

_Discussion

The atrophic areas augmented with the cement healed uneventfully and no per- or post-operative complication occurred in any of the two bone augmentation procedures performed in this study. Implant placement surgeries were also performed without any complication and all patients could eventually have their implant-supported prostheses in-

AD

www.AICimplant.com

AIC World Meeting

2009 THAILAND

OSSTEM IMPLANT,
The most dynamic evolution in the world!

2nd~3rd, May 2009
CENTARA GRAND HOTEL
in Bangkok, Thailand

Besuchen Sie OSSTEM; IDS Köln
Hall 4.1 A008,A010,A019,C019

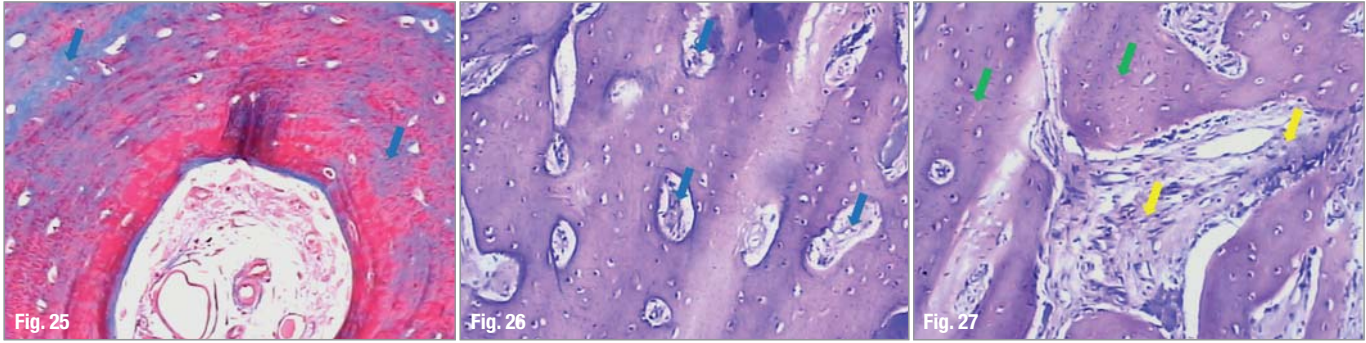


Infos und Teilnahme unter : OSSTEM Germany GmbH
Tel : +49 (0) 6196 777 5512 / de.osstem.com / www.aicimplant.com

PROGRAM

3rd, May 2009

Session	Speaker	Subject	Moderator	
Opening	09:30~10:00(30")	Opening		
Session 1	10:00~10:45(45")	Dr. Suh, Bong-hyeun	Early/immediate loading in surgically compromised patient	Dr. How Kim Chuan
	10:50~11:35(45")	Dr. Rajapsa Panichuttra	Esthetics CAD-CAM Abutments	Dr. Marius Mitrenca
	11:35~12:00(25")	Q & A		
Lunch	12:00~13:00(60")	Lunch		
Session 2	13:00~13:50(50")	Dr. Cho, Yong-seok	Advantages of OSSTEM GS Implant System	Dr. Yen-Ching Chang
	13:55~14:40(45")	Dr. Jun, In-sung	Why we have to go to a sinus lifting with simultaneous implantation rather than delayed implantation	Dr. Zhou Lei
	14:40~14:55(15")	Q & A		
Break	14:55~15:15(20")	Break		
Session 3	15:15~16:00(45")	Dr. Christopher Sim	An Assessment of the Clinical Performance of GSII Implant System	Dr. Ajit Shetty
	16:05~16:50(45")	Dr. Sung, Moo-gyung	Comprehensive approach in poor bone quality	Dr. Albert Lee
	16:55~17:30(35")	Dr. Cho, Yong-seok	Advantages of OSSTEM GS Implant System	Dr. Yen-Ching Chang
	17:30~18:00(30")	Q & A		
Closing	18:00	Closing		



Figs. 26, 27_ Histological sections from G2, magnified 10 and 40x (HE).

stalled as planned. The cement was easy to locate on all post-operative radiographs, especially in the sinus, and the healing process could be stated and followed through all follow-up times. The histological analysis of the sections allowed good interpretation of the results. The drilling during implant placement surgery found an osseous tissue of firm consistency, with good resistance to drilling with rotary instruments. This allowed implant installation with primary stability. Histologically, new bone formation could be clearly shown and explains the very favorable clinical conditions encountered upon placement of the implants. The sections showed the presence of viable bone tissue in the augmented areas (Figs. 22–30). Inside the trabeculae, signs of viable cells were found within the cellular spaces (Figs. 23 and 29).

Another interesting finding was the presence of incremental growth lines clearly seen in the bone trabeculae (Figs. 23 and 24). This was the evidence suggesting that an active bone remodeling process is taking place (Figs. 23–26). We also note the discrete to moderate presence of inflammatory mononuclear infiltrate in the medullary spaces (Figs. 22–25), a characteristic frequently encountered in medullary spaces, probably associated with the ongoing local bone healing process. At small magnifications, a larger bone density was observed in the augmented areas compared to the native bone areas (Figs. 17, 21 and 26).^{22, 23} All these findings lead us to conclude that the processes of bone neof ormation and remodeling were ongoing in the grafted areas. The good osteoconductive properties of the injectable cement allow deposition of newly

formed bone of good quality to support implants. We find three very valuable reasons for using the injectable PD VitalOs Cement: First, the time saved by not having to get autologous bone from a donor site, and the ease of handling that shortens the surgical procedures. Second, its excellent osteoconductive properties allowing deposition of newly formed bone at the bone-cement interface, and finally, the adequately slow resorption rate that avoids the loss of volume of the injected cement. These features are great advantages comparing to autologous bone. The spongy particulated autologous bone, known to be quickly remodeled, leads to considerable early loss of volume of the augmented areas.^{16, 17}

The three-dimensional microstructure of the material (porosity, surface area of particles, cohesion of particles and surface roughness) is certainly a key factor to the successful use of the product in vivo. The other key factor to success is the surgical procedure itself, which must follow a precise protocol, including important steps like careful drying of the site to ensure primary stability of the cement.

Conclusions

PD VitalOs Cement was used very efficiently as a bone grafting material. The histological sections of the areas augmented with the cement have shown the ability of the product to favour predictably osteogenesis, resulting in a firm osseous tissue once the cement is completely resorbed. In addition to these biological features, the product proved to be very easy to handle, reducing the trans-operative time and the trauma to the patient.

_contact	implants
<p>Dr Sérgio Alexandre Gehrke BioFace Institut Dr. Bozano, 571 Santa Maria – RS, Brazil E-mail: Sergio.gehrke@terra.com.br</p>	

Figs. 28–30_ Histological section from G2, magnified 4, 10 and 40x (TM).

